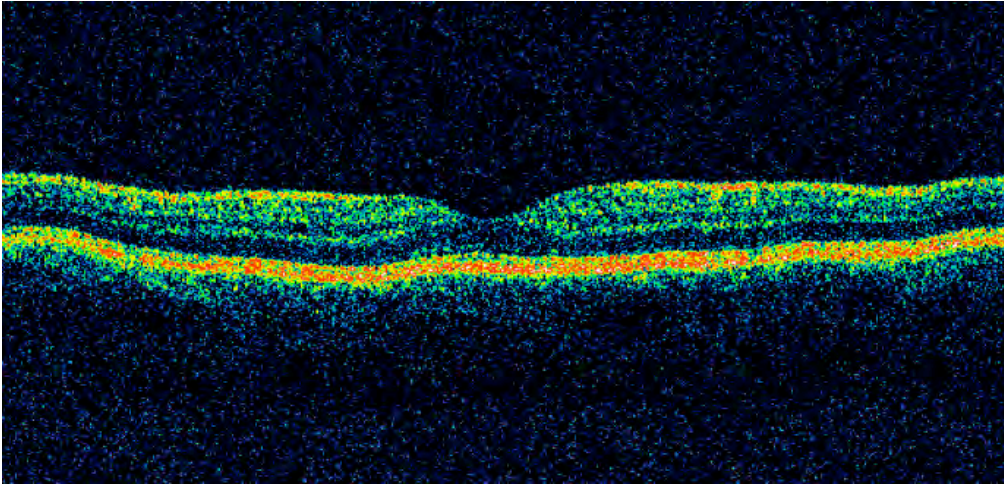
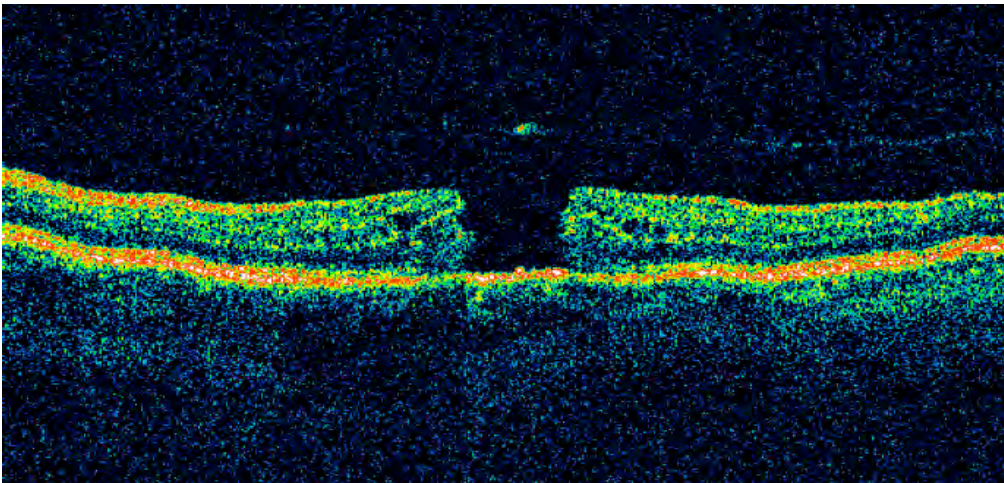


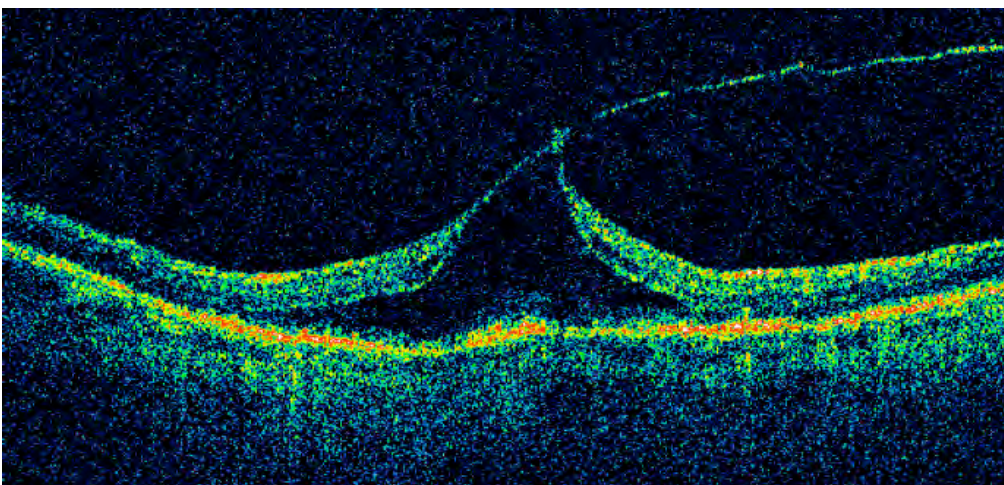
Optical Coherence Tomography:



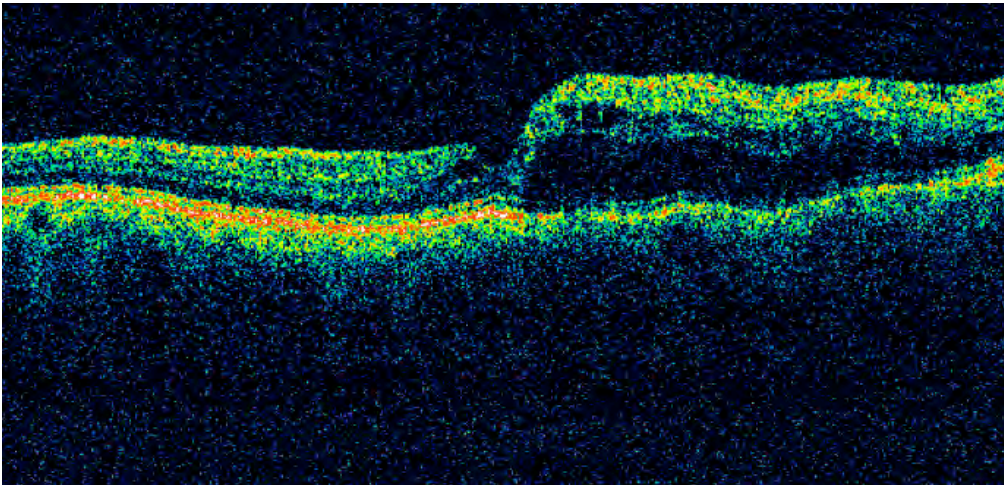
*This is a normal scan of the retina.*



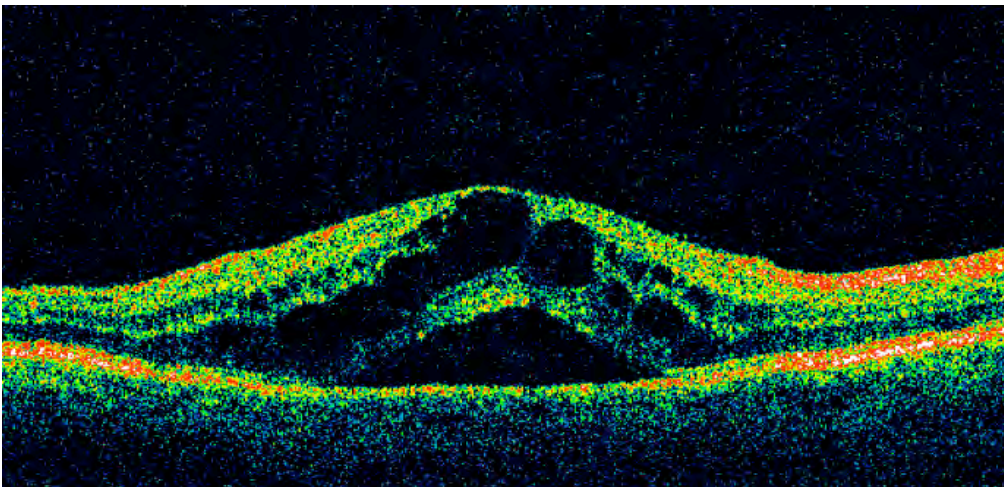
*In this scan, you can see a full thickness hole in the macula.*



*This scan shows an epiretinal membrane with vitreo-macular traction.*



*This OCT displays macular edema associated with a retinal vein occlusion.*



*This image shows cystoid macular edema following cataract extraction.*